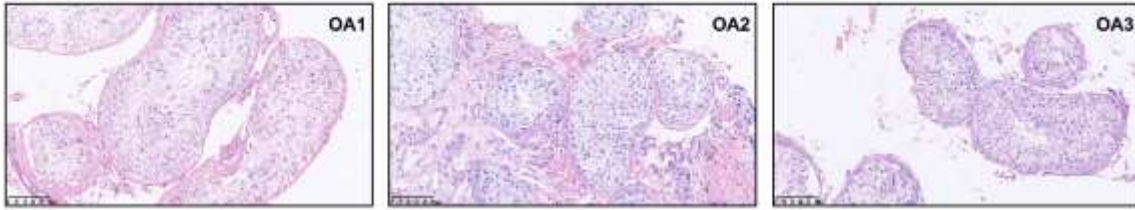
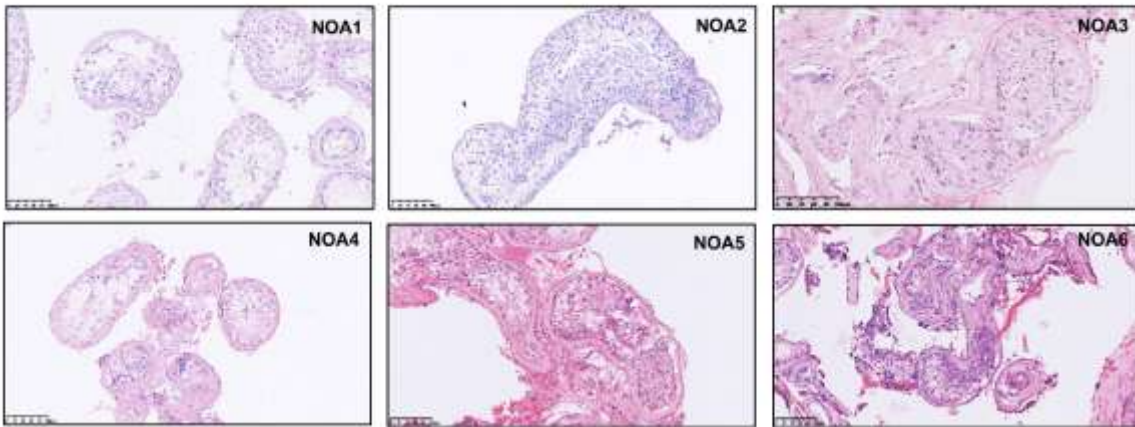


SUPPLEMENTARY FIGURE

A



B



Supplementary Figure 1. Histological pathological examinations of testis samples from 3 OA and 10 NOA patients. OA: obstructive azoospermia; NOA: non-obstructive azoospermia. Scale bar=100 μ m.